# Comparative study of endoscopic clips: duration of attachment at the site of clip application

**Eun Ji Shin, MD, Chung-Wang Ko, MD, Priscilla Magno, MD, Samuel A. Giday, MD, John O. Clarke, MD, Jonathan M. Buscaglia, MD, Gevorg Sedrakyan, MD, Sanjay B. Jagannath, MD, Anthony N. Kalloo, MD, Sergey V. Kantsevoy, MD, PhD**

Baltimore, Maryland, USA

**Background:** Several designs of endoscopic clips are now commercially available, and the indications for endoclip application are rapidly expanding. However, very limited data have been published to aid in choosing between the different types of endoclips.

**Objective:** To compare the duration of clip attachment between all commercially available endoclips.

**Setting:** Long-term experiments on 50-kg pigs under general anesthesia.

**Design and Interventions:** Upper endoscope was inserted into the stomach. One clip of each type (Resolution clip, TriClip, and HX-5L clip) was placed along the same gastric fold at a distance of 0.5 to 1 cm from each other. The animals were recovered. In pig nos. 1 and 2, repeat endoscopy was performed after 2 and 4 weeks. In pig nos. 3 to 5, endoscopy was repeated after 1, 2, and 5 weeks.

**Main Outcome Measurements:** Duration of clip retention at the site of application.

**Results:** In all animals, only the Resolution endoclip remained attached to the site of application for the entire duration of the study (4-5 weeks). No TriClips or HX-5L clips were attached at the 4- to 5-week follow-up endoscopies. Most of the TriClips (67%) detached within the first week after application. Most of the HX-5L clips (80%) dislodged within the first 2 weeks of follow-up.

**Limitations:** The study was performed in a porcine model with a small number of animals.

**Conclusions:** The Resolution clip has the longest duration of retention at the site of application (more than 4-5 weeks) and should be preferred when long-term attachment of endoclips is necessary. (Gastrointest Endosc 2007;66:757-61.)

The metallic endoscopic clip was first described as a therapeutic tool for hemostasis more than 30 years ago.[1] Widespread use of endoscopic clips was initially hindered by technical difficulties in deployment and low clip-retention rates.[2,3] Because of significant improvements in the design of the endoscopic clips, they are now routinely used for the treatment of nonvariceal GI bleeding.[2-4]

Several reports of nonhemostatic applications of endoscopic clips have been published, including closing mucosal defects and perforations,[5-10] managing anastomotic leaks,[11] placing enteral feeding tubes,[12-14] anchoring esophageal endoprosthesis,[15,16] and marking tumors before surgery,[17,18] radiation therapy,[19,20] and endoscopic examinations.[21]

Currently, there are several designs of endoscopic clips commercially available for use in human beings. Given the increased spectrum of therapeutic uses for endoscopic clips, different types of endoclips may offer advantages for specific uses. However, there are very limited data published to aid in the decision process in choosing among the available endoscopic clips. There are only 2 studies, presented in an abstract form, that compared different endoscopic clips for treatment of nonvariceal GI bleeding,[22,23] and 1 recent study compared the ''hemodynamic efficacy'' of the clips from Olympus Optical Co, Ltd, Tokyo, Japan, and from Cook Endoscopy, Winston-Salem, NC, on an isolated stomach model.[24] There are currently no studies published as full-length, peer-reviewed manuscripts that compared the use of available endoscopic clips for any other indications.

*Abbreviation: IV, intravenous.*

Copyright © 2007 by the American Society for Gastrointestinal Endoscopy
0016-5107/$32.00
doi:10.1016/j.gie.2007.03.1049

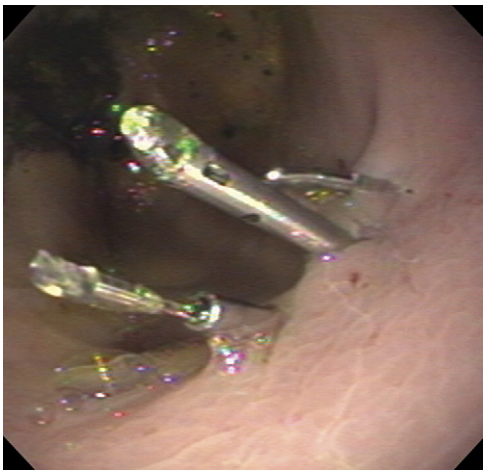

**Figure 1.** At the initial endoscopy, the 3 different endoclips are placed at the same gastric fold.

The duration of attachment of endoscopic clips at the site of its application is especially important when the clips are used to mark GI tumors to guide future surgery and radiation therapy, or when they are used to anchor endoprostheses and enteral feeding tubes. The aim of our study was to compare the duration of endoclip attachment for all commercially available endoscopic clips (from Cook, Olympus, and Microvasive Endoscopy, Boston Scientific Corp, Natick, Mass) in long-term survival animal experiments.

## MATERIALS AND METHODS

The study was approved by the Johns Hopkins University School of Medicine Animal Care Institutional Review Board. All experiments were performed on 50-kg pigs (*Sus scrofus domesticus*). Five consecutive 50-kg pigs underwent upper endoscopy with placement of endoscopic clips. All the pigs were then kept alive for 4 to 5 weeks.

The pigs were fed six 0.5 L (16-ounce) cans of Ensure (Abbott Laboratories, North Chicago, Ill) for 2 days and then were food deprived overnight before the endoscopic examination. Preanesthesia medication, which consisted of intramuscular injection of 100 mg/mL Telazol (tiletamine HCl + zolazepam HCl; Lederle Parenterals, Inc, Carolina, Puerto Rico) reconstituted with 100 mg/mL ketamine HCl and 100 mg/mL xylazine, at a total dose of approximately 0.05 mL/kg, was administered, and an intravenous (IV) line was placed in the marginal ear vein, with an infusion of 1 g thiopental sodium at a dose of 6.6 to 8.8 mg/kg IV. Normal saline solution was given by IV to replace fluid loss during the procedure. With the pig under general anesthesia with 1.5% to 2% isoflurane and 7.0-mm endotracheal intubation (Mallinckrodt Co, C. D. Juarez, Chihuahua, Mexico), an adult forward-viewing, double-channel endoscope (GIF-2T160; Olympus) was advanced into the esophagus and the stomach.

### Capsule Summary

**What is already known on this topic**

- Given the spectrum of their therapeutic uses, various types of endoscopic clips may offer advantages for specific uses.

**What this study adds to our knowledge**

- In a study that compared the retention rates of Microvasive Endoscopy Resolution clips, Cook Endoscopy TriClips, and Olympus HX-5L endoscopic clips in 5 pigs, the Resolution clips were retained longest at the gastric fold.

The 3 endoscopic clips used during our experiments were the Resolution Clip (Microvasive), the TriClip (Cook Endoscopy), and the HX-5L clip (Olympus). One clip of each type was placed along the same fold in the stomach at a distance of 0.5 to 1 cm from each other (Fig. 1).

At the conclusion of the endoscopic examination, the pigs were extubated and recovered from general anesthesia within 2 to 4 hours. The pigs were evaluated daily, and oral feedings with standard chow were resumed on postoperative day 1. In pig nos. 1 and 2, a repeat endoscopy was performed after a 2-week and a 4-week follow-up to evaluate the retention of the endoscopic clips. In pig nos. 3, 4, and 5, a repeat endoscopy was performed at 1-, 2-, and 5-week intervals. After the final endoscopy, the animals were euthanized, and postmortem examinations were performed with particular attention to the sites of endoclip application.

## RESULTS

In pig nos. 1 and 2, only the Resolution endoclip remained attached to the site of the application at the 2- and 4-week follow-up endoscopies. In pig no. 3, both the Resolution clip and the HX-5L clip remained attached at 1- and 2-week follow-ups. However, at the 5-week follow-up, only the Resolution clip was still attached to the gastric fold. In pig no. 4, 2 of the clips (Resolution clip and HX-5L clip) were visualized at the 1-week follow-up (Fig. 2), but at the 2- and 5-week follow-ups, only the Resolution clip remained (Figs. 3 and 4). In pig no. 5, all 3 endoclips were seen attached to the gastric wall at the 1-week follow-up. By the 2-week follow-up, only the Resolution clip remained at the site of application, and it was still attached to the gastric fold at the 5-week follow-up.

In a summary (Table 1), only the Resolution endoclip remained attached to the site of application for the entire duration of the study (4-5 weeks). Most of the TriClips (67%) were detached within the first week after

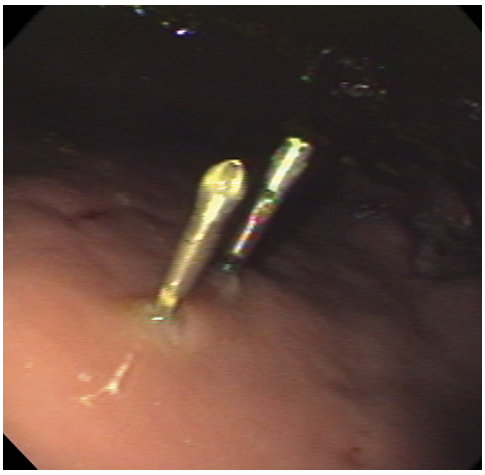

**Figure 2.** At the 1-week follow-up endoscopy, only 2 of the endoclips (HX-5L and Resolution) were still attached.

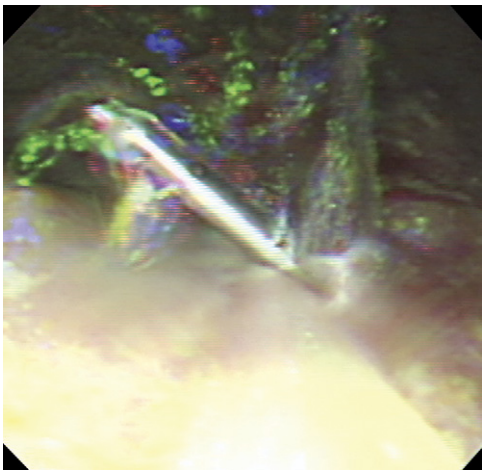

**Figure 4.** At the 5-week follow-up endoscopy, the Resolution clip is still attached.

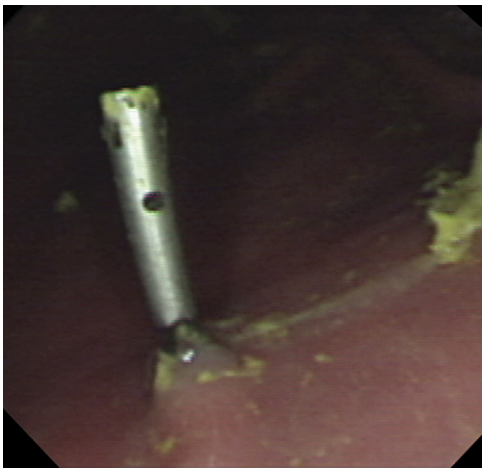

**Figure 3.** At the 2-week follow-up endoscopy both the Triclip and the HX-5L clips had already detached, with only the Resolution clip still attached.

**TABLE 1. Clips retained at follow-up endoscopy**

| | Clips still attached during follow-up endoscopy | | |
|---|---|---|---|
| Type of clip | 1 wk (n = 3) | 2 wk (n = 5) | 4-5 wk (n = 5) |
| Triclip | 1 | 0 | 0 |
| HX-5L | 3 | 1 | 0 |
| Resolution | 3 | 5 | 5 |

*n*, Number of pigs.

application, and all were lost within the first 2 weeks of observation. Most of the HX-5L clips (80%) were detached within the first 2 weeks after application.

There were no major complications from the retained or the detached metallic endoscopic clips. Postmortem examinations did not reveal any local tissue damage at the sites of endoscopic clips application.

## DISCUSSION

With the expansion of potential therapeutic uses for endoscopic clips, each of the available endoclip designs may offer specific advantages for particular uses. Unfortunately, there is currently a dearth of published data to aid in making an informed choice among the commercially available endoclips. Endoscopic clips used for hemostasis were previously reported to dislodge spontaneously 1 to 3 weeks after placement,[5] although there is a case report of a clip (HX-3L; Olympus) used for marking that remained at the site of its application for up to 26 months.[21] Another report where endoscopic clips (HX-3/4; Olympus) were used for tumor marking before radiation therapy demonstrated that the clips were no longer detectable by chest radiograph approximately 1 month after placement.[20]

Recently, there were 2 abstracts presented at Digestive Disease Week 2005 that compared retention rates of the 3 different endoscopic clips used for hemostasis of bleeding gastric ulcers in dogs at weeks 1 and 2.[22,23] The Resolution clip was retained more frequently than the Olympus clip, which in turn was retained better than the Triclip at both the 1- and 2-week follow-up.[22,23] Another recent study was performed on isolated stomachs (Erlangen Active Simulator for Interventional Endoscopy training model), and there was no significant difference between the Olympus and the Cook endoclips with respect to their ''hemostatic efficacy.''[24]

We performed a series of long-term survival experiments on a porcine model to compare the retention

rate at the site of application of the 3 different designs of endoscopic clips currently available for clinical use: Resolution clip, TriClip, and the HX-5L clip. In our study, the Resolution clip consistently remained attached at the site of its application for a longer period of time than both the HX-5L clip and the TriClip. The Resolution clip was the only endoscopic clip that remained attached to the site of its application for the entire duration of the experiments (4-5 weeks). The Triclip had already detached and was lost after 1 week of observation in the majority of the animals (67%), and was detached and lost in all animals after 2 weeks of observation. The HX-5L clip did not last significantly longer than the Cook clip: most Olympus clips (80%) were detached and lost after the first 2 weeks of observation, and all Olympus clips were lost before the end of the observation period (4-5 weeks).

The longer retention of the Resolution clip has potential benefits for many clinical indications. For example, in patients with esophageal cancer, the standard practice is to extend the radiation field at least 5 cm above and below the gross tumor borders to include adjacent lymph nodes.[25] With the need for clear delineation of tumor margins before radiation therapy to maximize therapeutic benefits and to decrease toxicity and adverse effects, accurate and long-lasting placement of metallic radiopaque endoscopic clip appears to be an attractive method for tumor marking, even if mucosal changes related to radiation therapy could potentially lead to clip dislodgement. A recent study reported that all 7 patients with esophageal cancer who had endoscopic clips placed for tumor marking before radiation therapy had the field of radiation changed when compared with the original measurements determined by the conventional practice.[19] Given that the typical duration of external-beam radiation therapy for esophageal cancer is between 4 and 6 weeks,[26-28] the longer retention rate period of the Resolution clip will have obvious clinical benefits.

The longer retention rate of an endoscopic clip may also be used in anchoring esophageal endoprostheses, especially in those patients with cancer of the distal esophagus and the cardia.[15,16] The most common complications associated with the placement of a self-expanding metal esophageal stent in malignant dysphagia are tumor ingrowth and stent migration.[29] To decrease the possibility of tumor ingrowth through the wire mesh, covered stents were introduced.[30,31] However, the covered stents have an increased risk of stent migration, especially when placed in tumors at or near the gastroesophageal junction, with migration rates as high as 27%.[16,32] It has also been noted that the majority of stent migration occurred within a month of placement.[33] Anchoring a self-expanding esophageal stent with an endoclip for at least 1 month can potentially prevent stent migration.[15,16] Our study demonstrated that, of all commercially available endoscopic clips, only the Resolution clip remained consistently attached at the site of application for 4 to 5 weeks.

The main limitation of our study is that it was performed on a porcine model with a relatively small number of animals. But, despite the small sample size, we had very consistent results that proved dislodgement of HX-5L clips and the TriClips in all animals within the first 2 weeks after application and demonstrated that the Resolution clip should be preferred when long-term attachment of the endoclips is necessary. Further clinical studies are currently planned to evaluate the duration of attachment of different endoclips in humans.

In conclusion, our long-term survival animal experiments demonstrated that Resolution clip had the longest duration of retention at the site of application (more than 4-5 weeks). This clip should be preferred when long-term attachment of endoclips is necessary, as is the case with tumor marking for future radiation therapy and when anchoring feeding tubes or self-expanding stents.

## DISCLOSURE

*None of the authors have any financial interest in any endoscopic clips. None of the authors have any conflict of interest to report.*

## REFERENCES


1. Hayashi T, Yonezawa M, Kuwabara T, et al. The study on staunch clip for the treatment by endoscopy. Gastrointest Endosc 1975;17:92-101.
2. Binmoeller KF, Thonke F, Soehendra N. Endoscopic hemoclip treatment for gastrointestinal bleeding. Endoscopy 1993;25:167-70.
3. Devereaux CE, Binmoeller KF. Endoclip: closing the surgical gap. Gastrointest Endosc 1999;50:440-2.
4. Raju GS, Gajula L. Endoclips for GI endoscopy. Gastrointest Endosc 2004;59:267-79.
5. Binmoeller KF, Grimm H, Soehendra N. Endoscopic closure of a perforation using metallic clips after snare excision of a gastric leiomyoma. Gastrointest Endosc 1993;39:172-4.
6. Wewalka FW, Clodi PH, Haidinger D. Endoscopic clipping of esophageal perforation after pneumatic dilation for achalasia. Endoscopy 1995;27:608-11.
7. Yoshikane H, Hidano H, Sakakibara A, et al. Endoscopic repair by clipping of iatrogenic colonic perforation. Gastrointest Endosc 1997;46:464-6.
8. Kaneko T, Akamatsu T, Shimodaira K, et al. Nonsurgical treatment of duodenal perforation by endoscopic repair using a clipping device. Gastrointest Endosc 1999;50:410-3.
9. Raju GS, Pham B, Xiao SY, et al. A pilot study of endoscopic closure of colonic perforations with endoclips in a swine model. Gastrointest Endosc 2005;62:791-5.
10. Raju GS, Ahmed I, Brining D, et al. Endoluminal closure of large perforations of colon with clips in a porcine model (with video). Gastrointest Endosc 2006;64:640-6.
11. Rodella L, Laterza E, De Manzoni G, et al. Endoscopic clipping of anastomotic leakages in esophagogastric surgery. Endoscopy 1998;30:453-6.
12. Ginsberg GG, Lipman TO, Fleischer DE. Endoscopic clip-assisted placement of enteral feeding tubes. Gastrointest Endosc 1994;40:220-2.
13. DeLegge MH, Kirby DF. Endoscopic clip assisted placement of enteral feeding tubes. Gastrointest Endosc 1995;41:179-80.

14. Frizzell E, Darwin P. Endoscopic placement of jejunal feeding tubes by using the Resolution clip: report of 2 cases. Gastrointest Endosc 2006; 64:454-6.
15. Sriram PV, Das G, Rao GV, et al. Another novel use of endoscopic clipping: to anchor an esophageal endoprosthesis. Endoscopy 2001;33: 724-6.
16. Silva RA, Dinis-Ribeiro M, Brandao C, et al. Should we consider endoscopic clipping for prevention of esophageal stent migration? Endoscopy 2004;36:369-70, author reply 370.
17. Hachisu T, Miyazaki S, Hamaguchi K. Endoscopic clip-marking of lesions using the newly developed HX-3L clip. Surg Endosc 1989;3: 142-7.
18. Kim SH, Milsom JW, Church JM, et al. Perioperative tumor localization for laparoscopic colorectal surgery. Surg Endosc 1997;11:1013-6.
19. Pfau PR, Pham H, Ellis R, et al. A novel use of endoscopic clips in the treatment planning for radiation therapy (XRT) of esophageal cancer. J Clin Gastroenterol 2005;39:372-5.
20. Weyman RL, Rao SS. A novel clinical application for endoscopic mucosal clipping. Gastrointest Endosc 1999;49:522-4.
21. Iida Y, Miura S, Munemoto Y, et al. Endoscopic resection of large colorectal polyps using a clipping method. Dis Colon Rectum 1994;37: 179-80.
22. Jensen DM, Machicado GA, Hirabayashi K. Hemoclipping (CLIP) of chronic ulcers: a randomized prospective study of initial success, clip retention rates, and ulcer healing [abstract]. Gastrointest Endosc 2005;61:AB174.
23. Machicado GA, Jensen DM, Hirabayashi K. A randomized comparative study of endoscopic hemoclips, thermal coagulation, and injection for bleeding canine acute gastric ulcers [abstract]. Gastrointest Endosc 2005;61:AB91.
24. Maiss J, Dumser C, Zopf Y, et al. ''Hemodynamic efficacy'' of two endoscopic clip devices used in the treatment of bleeding vessels, tested in an experimental setting using the compact Erlangen Active Simulator for Interventional Endoscopy (compactEASIE) training model. Endoscopy 2006;38:575-80.
25. Tran LM. Radiation therapy for esophageal carcinoma. In: Haskell CM, editor. Cancer treatment. Philadelphia: Saunders; 2001. p. 671-6.
26. Kelsen DP, Minsky B, Smith M, et al. Preoperative therapy for esophageal cancer: a randomized comparison of chemotherapy versus radiation therapy. J Clin Oncol 1990;8:1352-61.
27. Minsky BD, Pajak TF, Ginsberg RJ, et al. INT 0123 (Radiation Therapy Oncology Group 94-05) phase III trial of combined-modality therapy for esophageal cancer: high-dose versus standard-dose radiation therapy. J Clin Oncol 2002;20:1167-74.
28. Bates BA, Detterbeck FC, Bernard SA, et al. Concurrent radiation therapy and chemotherapy followed by esophagectomy for localized esophageal carcinoma. J Clin Oncol 1996;14:156-63.
29. Knyrim K, Wagner HJ, Bethge N, et al. A controlled trial of an expansile metal stent for palliation of esophageal obstruction due to inoperable cancer. N Engl J Med 1993;329:1302-7.
30. Tan BS, Mason RC, Adam A. Minimally invasive therapy for advanced oesophageal malignancy. Clin Radiol 1996;51:828-36.
31. Winkelbauer FW, Schofl R, Niederle B, et al. Palliative treatment of obstructing esophageal cancer with nitinol stents: value, safety, and long-term results. AJR Am J Roentgenol 1996;166:79-84.
32. Kozarek RA, Raltz S, Brugge WR, et al. Prospective multicenter trial of esophageal Z-stent placement for malignant dysphagia and tracheoesophageal fistula. Gastrointest Endosc 1996;44:562-7.
33. Saidi RF, Abedi M, Dorais J, et al. Spontaneous migration and subsequent retrieval of esophageal expandable metal stents (EEMS) after 168 placements [abstract]. Gastrointest Endosc 1997;45:AB81.

Received October 18, 2006. Accepted March 5, 2007.

Current affiliation: Division of Gastroenterology (E.J.S., P.M., S.A.G., J.O.C., J.M.B., G.S., S.B.J., A.N.K., S.V.K.), Johns Hopkins Hospital, Baltimore, Maryland, USA, Division of Gastroenterology (C.-W.K.), Department of Internal Medicine Taichung Veterans General Hospital, Taichung, Department of Internal Medicine (C.-W.K.), School of Medicine National Yang-Ming University, Taipei, Taiwan.

Reprint requests: Sergey V. Kantsevoy, MD, Division of Gastroenterology, Johns Hopkins Hospital, 1830 E Monument St, Rm 423, Baltimore, MD 21205.